



PATIENT

Chloe Stypula

SPECIES

Feline

BREED

DSH

SEX

Female Spayed

AGE

1.1.09

WEIGHT

11lbs

INTERPRETED BY

Maggie Machen Lamy,
DVM, DACVIM
(Cardiology)

HOSPITAL NAME

Perry Hall Animal
Hospital

REFERRING VET

Dr. Miller

INVOICE

28066

DATE

1.3.22

PRESENTING CLINICAL SIGNS

History: Grade 4/6 heart murmur PMI sternal. Asses prior to dental.

-Pertinent abnormal PE/Chem/CBC/UA Results: BW WNL.

-Current medications: None.

-Blood pressure: 120mmHg.

-Sedation used: Not required to complete full diagnostic ultrasound.

-Pertinent previous ultrasound results: No previous.

-STAT: Not requested

-Imaging performed by: Stephanie Warga RDCS, RVT.

ECHOCARDIOGRAM FINDINGS

2D, m-mode, color flow and doppler imaging is available. The left ventricular wall is normal in dimension. There is a diffusely hyperechoic endocardium consistent with fibrosis. The endocardium also appears mildly remodeled. The papillary muscles appear mildly remodeled. The left atrium is normal in size. Blood flow through the LVOT appears normal with no evidence of obstruction. The right atrium is normal in size. The right ventricle appears normal. The tricuspid valve appears normal in structure and mobility. Trace/mild tricuspid regurgitation. The mitral valve is normal in structure and mobility. No mitral regurgitation. Blood flow through the RVOT is mildly elevated in velocity based upon Doppler and color flow, likely secondary to tachycardia creating a benign outflow tract obstruction. No evidence of cardiac tumors or metastatic lesions on this scan.

CARDIAC CHART

FELINE CARDIAC PARAMETERS	BODY WEIGHT (kg)	HR (BPM)	IVSd (cm) (Moise, Pipers)	LVIDd (cm) (Moise, Pipers)	LWVd (cm) (Moise, Pipers)	FS (%)	EF (%)
NORMAL PARAMETER	-----	150-240	3.5-0.55	<2 (mean 1.5)	3.5-0.55	35-67	80-100
PATIENT	5.0	NM	0.49	1.25	0.45	62	93
FELINE CARDIAC PARAMETERS	LA/AO (Boon)	LA/AO HEART BASE (Swe) (Abbott)	LA 2D short axis Base view (cm) (Abbott)		LVOT VEL (m/s)	RVOT VEL (m/s)	E max (m/s)
NORMAL	<1.5	<1.3	<1.2		<1.6	<1.3	<0.9
PATIENT	NM	1.16	1.16		1.0	1.7	NM

Adapted from June Boon, Veterinary Echocardiography, 1998
Abbott J & MacLean H JVIM 2006;20: 111-119, Moise et al. Am J Vet Res 47:1476, 1986. Pipers et al. Am J Vet Res 40:882, 1979.

INTERPRETATION OF THE FINDINGS & FURTHER RECOMMENDATION

The only cause of a murmur identified is a heart rate dependent flow obstruction through the right ventricle (DRVOTO), which is a physiologic finding (i.e., benign and of little clinical significance). This type of flow murmur will wax and wane secondary to tachycardia and volume changes. There is however a significant amount of LV remodeling and fibrosis, which may be indicative of early pathology or simply represent a normal variant. Regardless, the left atrial dimension is normal, and there is minimal risk for complication at this time. Serial echocardiography will be necessary to determine progression and clinical relevance of the findings in the future.

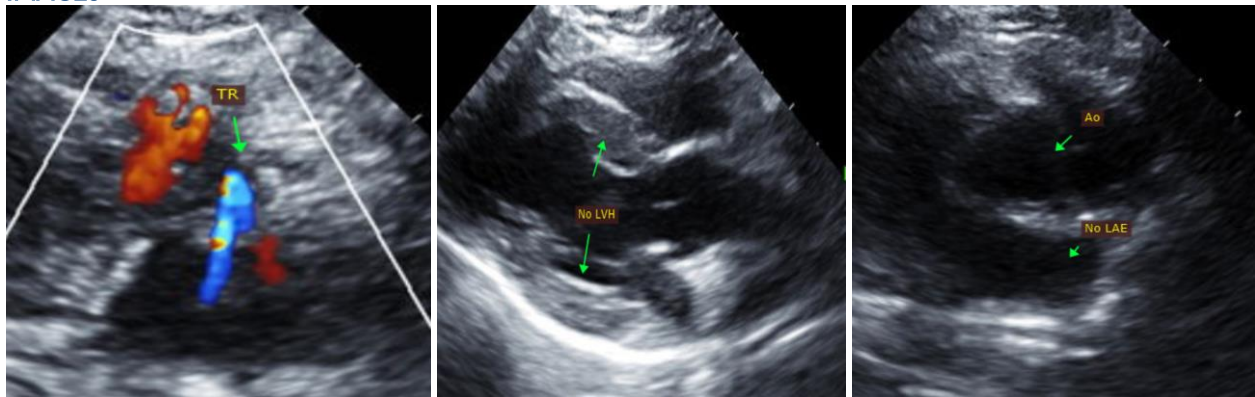
Given these findings, no medications are indicated at this time.

If needed, the risk for general anesthesia is low, however heart rate stimulating drugs such as atropine, glycopyrrolate or ketamine should be avoided unless medically necessary. Even without significant pathology, with this degree of remodeling and diastolic stiffening there is a mildly elevated risk for fluid overload in this patient. Judicious IV fluid use is recommended. Additionally, a screening blood pressure is recommended in any older cat prior to general anesthesia.

Risk for complication with steroid use typically follows LA dilation, which in this case is low. That being said, any cat can experience unexpected signs of intolerance and monitoring of RR/RE is advised particularly in the initiation phase.

Recommend recheck echocardiogram in 1 year to assess for progression or development of disease the pre-existing murmur may mask.

IMAGES



The information and recommendations provided are based on the images presented by the referring veterinarian. No evaluation can be communicated regarding pathology that was not visible in the image/video clips provided.

Thank you for this referral. This report was generated using transcription software, and minor dictation errors may be present. If the clinical or image interpretation does not parallel your findings or if I can be of any further assistance, please contact me.

Maggie Machen Lamy, DVM
Diplomate of the American College of Veterinary Internal Medicine (Cardiology)
info@sonopath.com